


## VACStent: a new option for endoscopic vacuum therapy in patients with esophageal anastomotic leaks after upper gastrointestinal surgery

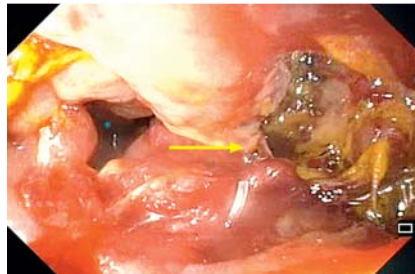
Esophageal anastomotic leaks remain a life-threatening postoperative complication of upper gastrointestinal surgery. In Germany, self-expandable metal stents (SEMS) and endoscopic vacuum therapy (EVT) are established endoscopic treatment options [1,2], but no evidence points to the superiority of either of these [3]. Consequently, new approaches aim to combine both procedures [4, 5]. One available medical device that combines EVT (sealing and drainage) with SEMS treatment (sealing and food passage) is a fully covered SEMS coated with a polyurethane foam (VACStent; Möller Medical GmbH, Fulda, Germany) (► **Fig. 1**). To our knowledge, this is the first report on using a hybrid SEMS for treating an esophageal anastomotic leak (► **Video 1**).

A 61-year-old man with an esophageal anastomotic leak (► **Fig. 2**) had undergone previous total gastrectomy for a signet cell carcinoma of the stomach. On the 16th postoperative day (POD), the patient was admitted to our hospital in a septic condition, having been treated unsuccessfully with an over-the-scope clip (Ovesco Endoscopy AG, Tübingen, Germany). We performed an endoscopy (POD 16) and discovered a semicircular anastomotic leak of the esophagojejunostomy with an abscess cavity. We removed the clip and applied a VACStent (125 mmHg negative pressure) to treat the leak. A computed tomography scan with oral contrast (► **Fig. 3**) confirmed sealing of the leak so that oral intake of fluids was possible.

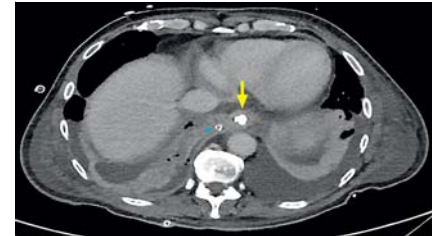The following endoscopy (POD 18) demonstrated a healing tendency; consequently, we placed a second VACStent. After VACStent removal (POD 22), we observed a sealed leak with a small and



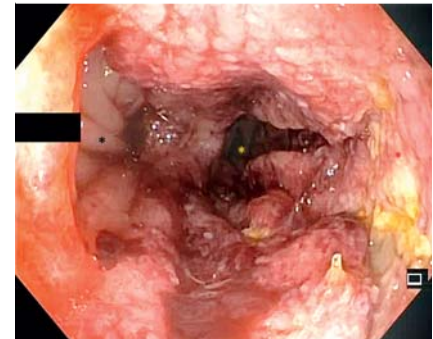
► **Fig. 1** VACStent: a fully covered, self-expandable metal stent (dimension 30 × 15 × 70 mm) coated with polyurethane foam and connected to a tube (blue).



► **Fig. 2** View of the esophagojejunal anastomosis: jejunum (blue asterisk) and anastomotic leak area (yellow arrow).



► **Fig. 3** Axial computed tomography with oral contrast showed complete sealing of the leak by the VACStent (yellow arrow) with a thoracic drain (asterisk).



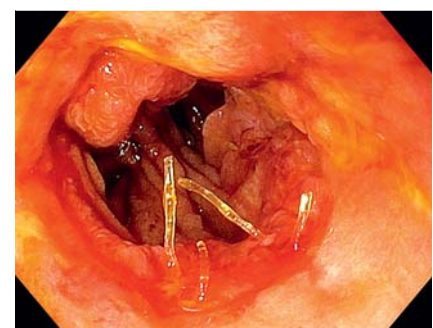► **Fig. 4** The sealed leak of the esophagojejunal anastomosis: blind loop jejunum (black asterisk), jejunum (yellow asterisk), and granulation of the wound cavity (red asterisk).

encapsulated wound cavity (► **Fig. 4**). A digestive swallowing test confirmed the sealing. Although the postoperative course was delayed because of pulmonary complications, the patient was discharged (POD 39) (► **Fig. 5**) with full oral intake and no clinical signs of a residual anastomotic leak.

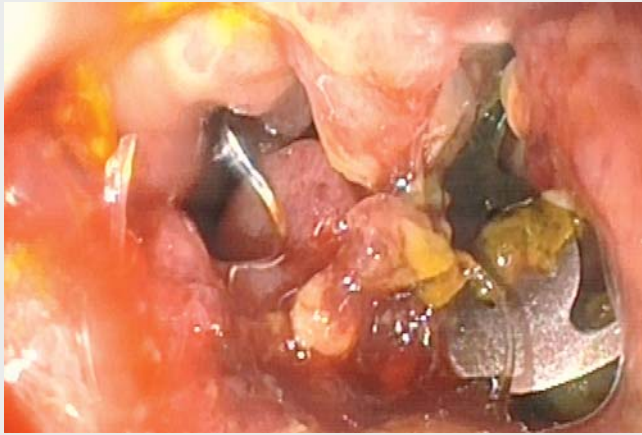Endoscopy\_UCTN\_Code\_TTT\_1AO\_2AI

### Competing interests

None



► **Fig. 5** Follow-up endoscopy 17 days after VACStent explantation.



**Video 1** Successful treatment of an esophageal anastomotic leak after gastrectomy with a novel hybrid stent.

- [3] Berlth F, Bludau M, Plum PS et al. Self-expanding metal stent versus endoscopic vacuum therapy on anastomotic leak treatment after oncologic gastroesophageal surgery. *J Gastrointest Surg* 2019; 23: 67–75
- [4] Vallo P, Mertens J, Kröger A et al. Stent-over-sponge (SOS): a novel technique complementing endosponge therapy for foregut leaks and perforations. *Endoscopy* 2018; 50: 148–153
- [5] Bartella I, Mallmann C, Bürger M et al. Stent-over-sponge (SOS): a rescue option in patients with complex postoperative anastomotic leaks after esophagectomy. *Endoscopy* 2019; 51: E227–E228

## Bibliography

DOI <https://doi.org/10.1055/a-1047-0244>  
Published online: 2.12.2019  
*Endoscopy* 2020; 52: E166–E167  
© Georg Thieme Verlag KG  
Stuttgart · New York  
ISSN 0013-726X

## The authors

Seung-Hun Chon<sup>1,2</sup>, Isabel Bartella<sup>1</sup>, Martin Bürger<sup>2</sup>, Isabel Rieck<sup>2</sup>, Tobias Goeser<sup>2</sup>, Wolfgang Schröder<sup>1</sup>, Christiane Josephine Bruns<sup>1</sup>

- 1 Department of General, Visceral, Cancer and Transplant Surgery, University of Cologne, Cologne, Germany
- 2 Department of Gastroenterology and Hepatology, University Hospital of Cologne, Cologne, Germany

## Corresponding author

**Seung-Hun Chon, MD**

Department of General, Visceral, Cancer and Transplant Surgery, University Hospital of Cologne, Kerpener Str. 62, 50937 Cologne, Germany  
Fax: +49-221-478 86227  
[seung-hun.chon@uk-koeln.de](mailto:seung-hun.chon@uk-koeln.de)

## References

- [1] Plum PS, Herbold T, Berlth F et al. Outcome of self-expanding metal stents in the treatment of anastomotic leaks after Ivor Lewis esophagectomy. *World J Surg* 2019; 43: 862–869
- [2] Bludau M, Fuchs HF, Herbold T et al. Results of endoscopic vacuum-assisted closure device for treatment of upper GI leaks. *Surg Endosc* 2018; 32: 1906–1914

## ENDOSCOPY E-VIDEOS

<https://eref.thieme.de/e-videos>



*Endoscopy E-Videos* is a free access online section, reporting on interesting cases and new techniques in gastroenterological endoscopy. All papers include a high quality video and all contributions are freely accessible online.

This section has its own submission website at  
<https://mc.manuscriptcentral.com/e-videos>